



Transrectal Prostate Biopsy After Prophylactic Preparation of the Rectum with Povidone-Iodine: A Prospective Randomized Trial

Biópsia Prostática Transretal Após Preparação Profilática do Recto com Iodo-Povidona: Estudo Prospectivo Randomizado

João Pedro Cadilhe

Abstract

Introduction: *Transrectal ultrasound guided prostate biopsy (TRUS-Bx), according to the literature, can lead to urinary tract infections in up to 11% and sepsis in up to 2% of patients. We evaluate whether an original way to apply povidone-iodine rectal preparation just prior to TRUS-Bx can reduce infectious complications.*

Material and Methods: *Between January 2014 and September 2016, 94 men in private office were prospectively randomized to two groups, before TRUS-Bx:*

- *Rectal cleansing (an original transrectal "prostate massage" for about half a minute with 2.5 mL of betadine dermic solution 100 mg/mL) (n=47) or*
- *No cleansing (n=47).*

All of the patients received prophylactic antibiotics: levofloxacin 500 mg PO for 7 days, beginning the day before procedure. Patients completed a telephone interview 4 days after undergoing the biopsy and went to the office 2 weeks after biopsy. The primary end point was the rate of infectious complications. An infectious complication when one or more of the following events occurred: 1) fever greater than 38.0°C, 2) urinary tract infection or 3) sepsis (standardized definition).

Student t test and multivariate regression analysis were used for data analysis.

Results: *Infectious complications developed in 6 cases (12.7%) in the non-rectal preparation group: five patients had fever without sepsis (11%) and one had sepsis (2%). In the povidone-iodine rectal preparation group there were no infectious complications (0.0%). Multivariate analysis did not identify any patient subgroups at significantly higher risk of infection after prostate biopsy.*

Of the 94 men who underwent TRUS-Bx 45 (47.9%) were diagnosed with prostate cancer and 3 (3.2%) had ASAP in the result. The hospital admission rate for urological complications within 30 days of the procedure was 1%, and only for infection related reasons (sepsis).

Conclusion: *The administration of quinolone-based prophylactic antibiotics and the simple use of 2.5 mL of povidone-iodine dermic solution in a transrectal prostate massage for*

Resumo

Introdução: A biópsia prostática transrectal (BPTR) ecoguiada, de acordo com a literatura actual, pode causar infecções do trato urinário em até 11% e sepsis em até 2% dos pacientes. Avaliamos a capacidade de uma forma original de preparação retal com iodo-povidona peri-procedimento (BPTR ecoguiada) poder reduzir complicações infecciosas.

Material e Métodos: Entre janeiro de 2014 e setembro de 2016, num estudo prospetivo e randomizado realizado num consultório privado, 94 homens foram divididos em dois grupos, antes da BPTR ecoguiada:

- Com preparação retal (uma original massagem prostática transrectal por cerca de meio minuto com 2,5 mL de betadina dérmica 100 mg/mL) (n=47)
- Sem preparação (n=47).

Todos os doentes receberam antibiótico profilático: levofloxacina 500 mg PO durante sete dias, iniciado no dia anterior ao procedimento. Os pacientes completaram uma entrevista por telefone quatro dias após a realização da biópsia e foram ao consultório médico duas semanas após a biópsia. O objectivo primário foi a comparação da taxa de complicações infecciosas. Foi considerada complicação infecciosa a ocorrência de um ou mais dos seguintes eventos: 1) febre superior a 38,0°C, 2) infecção do trato urinário ou 3) sépsis (definição padronizada). Foi utilizado o teste t de *Student* e a análise de regressão multivariada no estudo dos dados.

Resultados: No grupo sem preparação retal, seis pacientes (12,7%) tiveram complicações infecciosas: cinco apresentaram febre sem sépsis (11%) e um evoluiu com sépsis (2%). No grupo da preparação retal com iodo-povidona solução dérmica não se registaram complicações infecciosas (0,0%). A análise multivariada não identificou nenhum subgrupo de pacientes com risco significativamente maior de infecção após a biópsia da próstata.

Dos 94 homens que foram submetidos a BPTR ecoguiada, 45 (47,9%) foram diagnosticados com cancro da próstata e 3 (3,2%) apresentaram ASAP no resultado. A taxa de admissão hospitalar por complicações urológicas no prazo de 30 dias do procedimento foi de 1%, e apenas por razões relacionadas com infecção (sépsis).

Conclusão: A administração de antibióticos profiláticos à base de quinolonas e a simples aplicação de 2,5 mL de solução de iodo-

about half a minute provided an excellent protocol for reducing infectious complications of TRUS-Bx.

Keywords: Antibiotic Prophylaxis; Biopsy; Endoscopic Ultrasound-Guided Fine Needle Aspiration; Iodo-Povidona; Povidone-Iodine; Prostate.

Introduction

When prostate biopsy has to be performed, a great effort should be made to have optimal conditions to minimize morbidity and to provide adequate samples to the pathologist. It has been largely demonstrated that the use of local anesthesia effectively reduces patient's discomfort.¹⁻⁶

It is known that prostate biopsy samples require proper handling, adequate processing and an accurate pathological evaluation.⁵ Nowadays, at least 10 to 12 biopsy cores, predominantly from the peripheral zone of the prostate, are expected to be taken in order to maximize cancer detection rate.^{5,7-14} Moreover, additional biopsies of hypo-echogenic suspicious areas can further improve the detection rate.¹⁵⁻¹⁷ Iczkowski *et al* demonstrated that the length of the biopsy correlates with the prostate cancer detection rate, stressing the importance of the biopsy technique.¹⁸ On the other hand transrectal ultrasound-guided prostate biopsy (TRUS-Bx) can lead to urinary tract infections in up to 11% and sepsis in up to 2% of patients.¹⁹

Evidence supporting the protective effect of prebiopsy bowel preparation varies based upon the agent used for rectal cleansing. The majority of studies investigating enemas (using sodium phosphate or saline) found no protective effect against post-TRUS-Bx infections.²⁰⁻²²

In the era of quinolone resistance, a povidone-iodine enema may reduce the infectious complication rate by reducing bacterial load.²³

The aim of this study was to evaluate whether an original way to apply peri-procedure povidone-iodine dermic rectal preparation prior to TRUS-Bx can reduce infectious complications.

Material and Methods

Between January 2014 and September 2016, 94 men in private office were prospectively randomized to two groups, before TRUS guided prostate biopsy with periprostatic local injection of lidocaine, performed with Mini Focus BK scanner:

- Rectal cleansing (an original transrectal "prostate massage" for about half a minute with 2.5 mL of betadine dermic solution 100 mg/mL – Fig. 1) (n = 47) or
- No cleansing (n = 47).

All of the patients received a fluoroquinolone (FQ) prophylactic antibiotic: levofloxacin 500 mg *per os* for 7 days, beginning the day before procedure. Twelve cores were usually taken predominantly on the lateral aspect of the prostate peripheral zone (Fig. 2). Biopsies were delivered and embedded after flattening the cores between nylon sponges in a cassette (Fig. 3). The groups were comparable in terms of co-morbidities and age averages (Table 1). Patients completed a telephone interview 4 days after undergoing the biopsy and went to doctor office 2 weeks after biopsy. The primary end point was the rate of infectious complications, a

-povidona através de uma massagem transrectal da próstata por cerca de meio minuto proporcionaram um excelente protocolo para reduzir as complicações infecciosas da BPTR ecoguiada.

Palavras-chave: Aspiração por Agulha Fina Guiada por Ultrassom Endoscópico; Biópsia; Profilaxia Antibiótica; Próstata.



Figure 1: Syringe with 2.5 mL povidone-iodine dermic solution for easy rectal introduction.

composite end point of 1 or more of: 1) fever greater than 38.0C, 2) urinary tract infection or 3) sepsis (standardized definition).

Student t test and multivariate regression analysis were used for data analysis.

Results

Infectious complications developed in six cases (12.6%) in the non-rectal preparation group: one patient had sepsis (2%) and five patients had fever without sepsis (11%). In the povidone-iodine rectal preparation group we had no infectious complication (0.0%) (Fig. 4). Multivariate analysis did not identify any patient subgroups at significantly higher risk of infection after prostate biopsy.

Of the 94 men who underwent TRUS guided biopsy 45 (47.9%) were diagnosed with prostate cancer and three (3.2%) had ASAP in the result. The hospital admission rate for urological complications within 30 days of the procedure was 1%, and only for infection related reasons (sepsis).

The small sample size have not limited the conclusions from our study, with statistically significant relative risk reduction of infectious complications in rectal cleansing group (p 0.0057).

Discussion

Initial research indicates that transperineal prostate biopsy may be equally effective as transrectal ultrasound-guided prostate biopsy (TRUS-Bx) for detecting prostate cancer with a lower incidence of severe infections.²⁴ Transperineal biopsy poses a lower risk for infection because the method avoids seeding of the prostate gland with rectal flora.²⁵

Transrectal ultrasound-guided prostate biopsy is still being one of the most common urologic procedures performed worldwide, with over 1 million biopsies annually performed in the United States alone.²⁶

Among the variables found to be associated with post-TRUS-Bx infection, prior antibiotic exposure is the most extensively studied. Multiple studies document a strong association between prior antibiotic exposure and the risk of harboring FQ-resistant organisms.²⁷ However, an international prospective study failed to find an association between prior antibiotic exposure and an increased risk

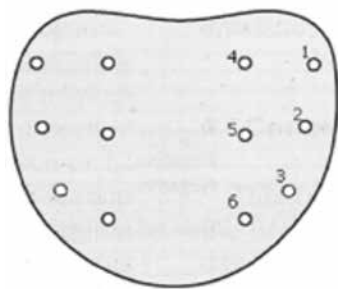


Figure 2: Scheme of 12 cores prostate biopsy.

for infectious complications ($p > 0.05$).²⁸ On the other hand a history of prior biopsies has also not definitively shown to increase patients' risk for post-TRUS-Bx infection.²⁹ We already know that augmented prophylaxis has consistently demonstrated superior protection compared with monotherapy.³⁰ FQs were most frequently coupled with aminoglycosides, specifically gentamicin and amikacin, in augmented prophylactic protocols. In a retrospective study, Lorber *et al* reported an 83% reduction in urosepsis by augmenting FQ prophylaxis with a single 240 mg dose of intramuscular (IM) gentamicin (3.6% vs 0.6%; $p = 0.04$). Data suggest that augmented prophylaxis is warranted in regions with high rates of antimicrobial resistance, with aminoglycosides as the most appropriate adjunct to FQ prophylaxis.³¹ Carbapenems were also frequently used in augmented protocols. In a recent New Zealand study, adding ertapenem to standard prophylaxis (ciprofloxacin and amoxicillin/ clavulanic acid) substantially reduced rates of sepsis in a high risk group (6.7% [95% CI, 2.1–11.3] vs 0%; $p = 0.03$).³² Although the literature supporting augmented prophylaxis in TRUS-Bx is robust, a number of shortcomings should be noted. Augmented prophylaxis is only a temporary solution to increased antimicrobial resistance, and widespread use of combinations of antibiotics will further exacerbate selection pressure for resistant microbes.²⁹




Figure 3a: The cores are flattening on nylon sponges.




Figure 3b: Embedded in position in a cassette.

Table 1: Comparisons in terms of co-morbidities and mean ages between groups

	Average ages	Hypocoagulated (number of patients)	Chronic urethral cateter (number patients)	Re-biopsy (number of patients)
Group without rectal cleansing	67 +/- 5	1	2	2
Group with rectal cleansing	69 +/- 6	2	3	3

Formalin disinfection has also been proposed as a cost-neutral means to reduce infectious complications. A recent report by Issa *et al* suggests that using formalin (10%) wash to disinfect the needle tip after each biopsy core sampling may minimize post-TRUS-Bx infections.³³

Povidone-iodine offers a number of advantages in reducing post-TRUS-Bx infections by decreasing rectal microbial counts prior to procedures in vitro, rapidly exerting its effects, and discouraging antimicrobial resistance.³⁴

Conclusion

Rising infection rates following TRUS-Bx are an urgent concern given the increased associated cost and morbidity.

The administration of quinolone-based prophylactic antibiotics and the simple use of 2.5 mL of povidone-iodine solution in a transrectal prostate massage for about half a minute provided an excellent protocol for reducing infective complications of TRUS-guided prostate biopsy. ●

Responsabilidades Éticas

Conflitos de Interesse: Os autores declaram a inexistência de conflitos de interesse na realização do presente trabalho.

Fontes de Financiamento: Não existiram fontes externas de financiamento para a realização deste artigo.

Proteção de Pessoas e Animais: Os autores declaram que os procedimentos seguidos estavam de acordo com a Declaração de Helsínquia da Associação Médica Mundial.

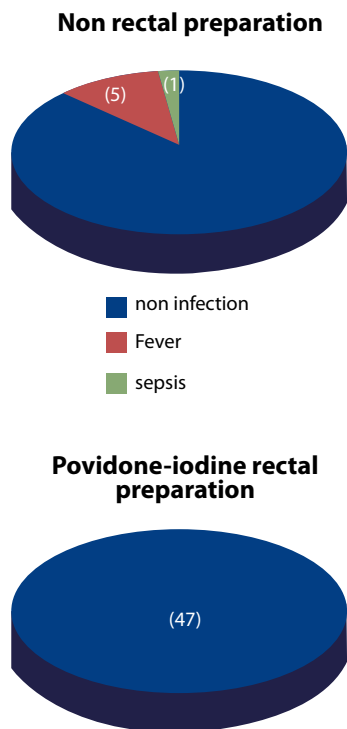


Figure 4: Results.

Confidencialidade dos Dados: Os autores declaram ter seguido os protocolos do seu centro de trabalho acerca da publicação dos dados de doentes.

Ethical Disclosures

Conflicts of interest: The authors report no conflict of interest.

Funding sources: No subsidies or grants contributed to this work.

Financing Support: This work has not received any contribution, grant or scholarship.

Protection of Human and Animal Subjects: The authors declare that the procedures followed were in accordance with the regulations of the relevant clinical research ethics committee and with those of the Code of Ethics of the World Medical Association (Declaration of Helsinki).

Confidentiality of Data: The authors declare that they have followed the protocols of their work center on the publication of patient data.

Corresponding Author/Autor Correspondente

José Pedro Cadilhe
 Serviço de Urologia, Unidade Local de Saúde do Alto Minho,
 Estrada de Santa Luzia 4901-858
 Viana do Castelo, Portugal
 E-mail: jpcadilhe@sapo.pt

Recebido/Received: 2017-06-12

Aceite/Accepted: 2017-06-12

REFERENCES

1. Issa MM, Bux S, Chunt T, Petros JA, Labadia AJ, Anastasia K, et al. A randomized prospective trial of intrarectal lidocaine for pain control during transrectal prostate biopsy. The Emory University experience. *J Urol.* 2000; 164:397-9.
2. Machado MT, Verotti MJ, Aragao AJ, Rodrigues AO, Borrelli M, Wroclawski E. Prospective randomized controlled trial comparing three different ways of anesthesia in TRUS guided Prostate Biopsy. *Int Braz J Urol.* 2006;32:172-80.
3. Nash PA, Shinohara K. TRUS guided prostatic nerve blockade eases systematic needle biopsy of the prostate. *J Urol.* 1996; 155: 607-9.
4. Soloway MS, Obek C. Periprostatic local anesthesia before ultrasound guided prostatic biopsy. *J Urol.* 2000; 163:172-3.
5. Cadilhe JP. TRUS prostatic Biopsy: the role of the Urologist step by step. *J Endourology.* 2006;20:170.

6. Autorino R, De Sio M, Di Lorenzo, Damiano R, Damiano R, Perdonà S, Cindolo L, et al. How to decrease pain during TRUS guided biopsy: a look at the literature. *J Urol.* 2005;174:2091-97.
7. Scattoni V, Zlotta A, Nava L, Rosigno M, Montorsi F. TRUS guided biopsy schemes and TRUS prostatic lesion guided biopsies. *Eur Urol.* 2002;Supl;28-34.
8. Rocco B, de Cobelli O, Leon ME, Ferruti M, Mastropasqua MG, Matei DV, et al. Sensitivity and detection rate of a 12-core trans-perineal prostate biopsy: preliminary report. *Eur Urol.* 2006;49:827-33.
9. Eskicorapci SY, Baydar DE, Akball C, Sofikerim M, Günay M, Ekici S, et al. An extended 10-core TRUS prostate guided biopsy protocol improves detection of prostate cancer. *Eur Urol.* 2004;45 444-9.
10. Emiliozzi P, Scarpone P, DePaula F, Pizzo M, Federigo G, Pansadoro A, et al. The incidence of prostate cancer in men with PSA greater than 4,0 ng/ml: a randomized study of 6 versus 12 core transperineal prostate biopsy. *J Urol.* 2004;171:197-9.
11. Ravery V, Goldblatt L, Royer B, Blanc E, Toubanc M, Boccon-Gibod L. Extensive biopsy protocol improves the detection rate of prostate cancer. *J Urol.* 2000;164:393-6.
12. Gore JL, Shariat SF, Miles BJ, Kadmon D, Jiang N, Wheeler TM, et al. Optimal combinations of systematic sextant and laterally directed biopsies for the detection of prostate cancer. *J Urol.* 2001;165:1554-9.
13. Chang JJ, Shinohara K, Bhargava V, Presti JC. Prospective evaluation of lateral biopsies of the peripheral zone for prostate cancer detection. *J Urol.* 1998;160:2111-4.
14. Terris MK, Wallen EM, Stamey TA. Comparison of mid-lobe versus lateral systematic sextant biopsies in detection of prostate cancer. *Urol Int.* 1997;59:239-42.
15. Cadilhe JP, Veiga da Silva. Esquemas de biopsias prostaticas transextais ecoguiadas e BPTR dirigidas a lesões. *Acta Urol Port.* 2007, 24;2:66.
16. Hodge KK, McNeal JE, Terris MK, Stamey TA. Random systematic versus directed ultrasound guided transrectal core biopsies of the prostate. *J Urol.* 1989;142:71-4.
17. Kuligowska E., Barish MA, Fenlon HM, Blake M. Predictors of prostate carcinoma: accuracy of gray scale and color doppler US and serum markers. *Radiology.* 2001;220:757-64.
18. Iczkowski KA, Casella G, Seppala RJ, Jones GL, Mishler BA, Qian J, et al. Needle core length in sextant biopsies influences prostate cancer detection rate. *Urology.* 2002;59:698-703.
19. Cadilhe JP. Transrectal prostate biopsy after prophylactic preparation of the rectum with povidone-iodine – A prospective randomized trial. *J Urol.* 2017;197:e143.
20. Carey JM, Korman HJ. Transrectal ultrasound guided biopsy of the prostate. Do enemas decrease clinically significant complications? *J Urol.* 2001; 166:82-5.
21. Zaytoun OM, Anil T, Moussa AS, Jianbo L, Fareed K, Jones JS. Morbidity of prostate biopsy after simplified versus complex preparation protocols: assessment of risk factors. *Urology.* 2011; 77:910-4.
22. Grabe M, Bjerklund-Johansen T, Botto H, et al. Guidelines on urological infections. European Association of Urology website [accessed April 2016] Available from: http://uroweb.org/wp-content/uploads/18_Urological-infections_LR.pdf.
23. Hwang EC, Jung SI, Seo YH, Jeong SH, Kwon DD, Park K, et al. Risk factors for and prophylactic effect of povidone-iodine rectal cleansing on infectious complications after prostate biopsy: a retrospective cohort study. *Int Urol Nephrol.* 2015; 47:595-601.
24. Murphy DG, Weerakoon M, Grummet J. Is zero sepsis alone enough to justify transperineal prostate biopsy? *BJU Int.* 2014; 114:3-4.
25. Grummet JP, Weerakoon M, Huang S, Lawrentschuk N, Frydenberg M, Moon DA, et al. Sepsis and 'superbugs': should we favour the transperineal over the transrectal approach for prostate biopsy? *BJU Int.* 2014; 114:384-8.
26. Loeb S, Carter HB, Berndt SI, Ricker W, Schaeffer EM. Complications after prostate biopsy: data from SEER-Medicare. *J Urol.* 2011;186:1830-4.
27. Akduman B, Akduman D, Tokgöz H, Erol B, Türker T, Ayoglu F, et al. Long-term fluoroquinolone use before the prostate biopsy may increase the risk of sepsis caused by resistant microorganisms. *Urology.* 2011; 78:250-5.
28. Wagenlehner FM, van Oostrum E, Tenke PG, GPIU investigators. Infective complications after prostate biopsy: outcome of the Global Prevalence Study of Infections in Urology (GPIU) 2010 and 2011, a prospective multinational multicentre prostate biopsy study. *Eur Urol.* 2013;63:521-7.
29. Walker JT, Singla N, Roehrborn CG. Reducing infectious complications following transrectal ultrasound-guided prostate biopsy: a systematic review. *Rev Urol.* 2016;18:73-89.
30. Womble PR, Linsell SM, Gao Y, Ye Z, Montie JE, Gandhi TN, et al. A statewide intervention to reduce hospitalizations after prostate biopsy. *Urological Surgery Improvement Collaborative.* *J Urol.* 2015; 194:403-9.
31. Lorber G, Benenson S, Rosenberg S, Gofrit ON, Pode D. A single dose of 240 mg gentamicin during transrectal prostate biopsy significantly reduces septic complications. *Urology.* 2013; 82:998-1002.
32. Losco G, Studd R, Blackmore T. Ertapenem prophylaxis reduces sepsis after transrectal biopsy of the prostate. *BJU Int.* 2014; 113 (Suppl 2):69-72.
33. Issa MM, Al-Qassab UA, Hall J, Ritenour CW, Petros JA, Sullivan JW. Formalin disinfection of biopsy needle minimizes the risk of sepsis following prostate biopsy. *J Urol.* 2013;190:1769-75.
34. Park DS, Hwang JH, Choi DK, Gong IH, Hong YK, Park S, et al. Control of infective complications of transrectal prostate biopsy. *Surg Infect.* 2014; 15:431-6.