



## Paratesticular Angioleiomyoma: A Case Report

### Angioleiomioma Paratesticular: Um Relato de Caso

Gustavo Chaves de Souza,<sup>1</sup> Ana Carolina Costa Tôres,<sup>2</sup> Lucas Soares Simizo Benedicto,<sup>2</sup> Manoel Vitor Franco Dourado,<sup>1</sup> Rodrigo Guimarães Corradi<sup>2</sup>

#### Abstract

Angioleiomyoma is a benign tumor that commonly affects the soft tissues of the extremities. Its presentation in the testicular region is rare and scarcely described in medical literature. In this case, its diagnosis occurred in a 50-year-old man with reports of chronic pain and a tumor in the left inguinal region. Due to limited scientific literature on the subject, with few described reports, preoperative diagnosis is still challenging and the approach is undefined.

**Keywords:** Angiomyoma; Testicular Neoplasms

#### Resumo

O angioleiomioma é um tumor benigno que comumente afeta os tecidos moles de extremidades. Sua apresentação em região testicular é rara e pouco descrita na literatura médica. Neste caso, seu diagnóstico ocorreu em um homem de 50 anos com relato de dor e tumoração crônica em região inguinal esquerda. Devido a literatura científica limitada sobre o tema, com poucos relatos descritos, o diagnóstico pré-operatório ainda é difícil e a abordagem não definida.

**Palavras-chave:** Angiomioma; Neoplasias Testiculares

#### Introduction

Angioleiomyoma is a benign tumor arising from vascular smooth muscle, with a higher incidence between the third and fifth decades of life, being more common in females.<sup>1</sup> This neoplasm tends to affect the subcutaneous tissue of the extremities and to a lesser extent the head and neck,<sup>2</sup> therefore, testicular involvement is uncommon.<sup>3</sup> Given its rarity, knowledge of this condition becomes important.

#### Case Report

A 50-year-old man was referred to the Urology service complaining of a lesion in the left inguinal region that had been progressively growing for 20 years, associated with local pain. He denied

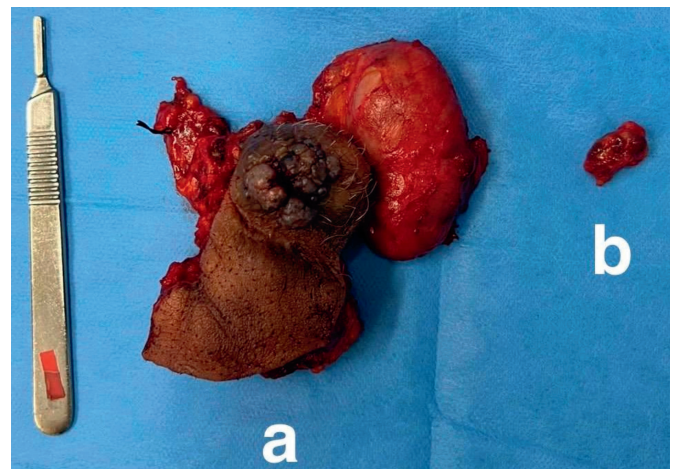
weight loss and urinary changes. The clinical examination revealed a hardened, exophytic, and ulcerated lesion in the inguinal region and the upper third of the left scrotum, apparently involving the ipsilateral spermatic cord, in addition to bilateral inguinal lymphadenopathy.

The abdominal computed tomography scan revealed a lesion with contrast enhancement in the left inguinal region measuring 4.5x2.7 cm of undetermined aspect, in addition to lymphadenopathies in the inguinal regions.

The patient was informed about the possibility of neoplasia and the possible need for associated orchiectomy. He underwent partial resection of the scrotal bag and left orchiectomy and ipsilateral inguinal lymphadenectomy during surgery due to observed morphological changes. Fig. 1 presents an image of the specimen after excision.

During the anatomopathological evaluation, a brownish-white paratesticular lesion was observed, measuring 2.4 cm at its largest axis. The testicle itself had dimensions of 6.5x3.8x2.3 cm, with a smooth, light-brown capsule-covered surface, and the usual macroscopic aspects. A larger resection was performed in order to leave a free margin of the neoplastic lesion.

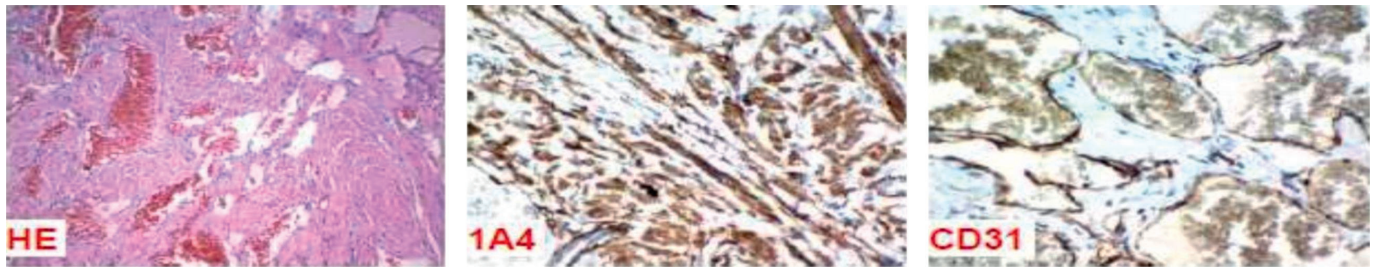
Under the microscope, the paratesticular lesion revealed mesenchymal neoplasia, with expansive growth, consisting of spindle cell proliferation with eosinophilic cytoplasm, without nuclear atypia, arranged in short, disordered bundles around numerous tortuous and dilated blood vessels (Fig. 2. HE), being



**Figure 1:** Product of partial resection of scrotal pouch and left testicle with surgical margins (a), and left inguinal lymph node (b).

1 – Universidade Professor Edson Antônio Velano (UNIFENAS), Belo Horizonte, Minas Gerais, Brasil

2 – Hospital Luxemburgo Instituto Mario Penna, Belo Horizonte, Minas Gerais, Brasil



**Figure 2:** Microscopic images of the paratesticular lesion in hematoxylin-eosin and immunohistochemical studies. HE: Mesenchymal neoplasia is observed, without nuclear atypia, with presence of spindle cells with eosinophilic cytoplasm, arranged in short and disordered bundles around numerous tortuous and dilated blood vessels. 1A4: Diffuse cytoplasmic expression for smooth muscle actin, highlighting muscle fibers. CD31: Diffuse cytoplasmic expression for CD31, highlighting the blood vessel walls.

morphologically consistent with angioleiomyoma. The testicular parenchyma and the inguinal lymph node showed no evidence of neoplastic disease. Immunohistochemical study revealed diffuse positivity for smooth muscle actin (Fig. 2. 1A4) and desmin in muscle fibers, and CD31 (Fig. 2. CD31) and ERG in the vessel walls, corroborating the diagnosis of angioleiomyoma.

In the postoperative period, there were no complications and the patient was discharged, returning later in excellent general health and without clinical complaints.

## Discussion

Tumoral proliferations of the testicular appendages are uncommon and indistinguishable from malignant neoplasms before proper surgical approach.<sup>4</sup> Occasionally, these tumors can simulate malignancy,<sup>5</sup> contributing to diagnostic uncertainty.

Mesenchymal tumors of the paratesticular region present clinically in a similar manner, often as painless masses of variable growth. The distinction between these lesions is made mainly through histopathological and immunohistochemical examinations, given the clinical overlap. Microscopic evaluation reveals distinct cellular and structural features, while immunohistochemistry is essential for diagnostic confirmation, using panels of antibodies to mark specific tumor cell proteins.<sup>6-8</sup>

Among the types of tumors we have leiomyosarcoma, which is a malignant tumor derived from smooth muscle cells, exhibits spindle cells with nuclear atypia and increased mitotic activity with positive immunohistochemistry for smooth muscle actin, desmin and H-caldesmon. The myofibroblastoma is a benign tumor composed of myofibroblasts that displays spindle cells with abundant collagen in the stroma and presents positive immunohistochemistry for vimentin, smooth muscle actin and desmin, but negative for S-100. The aggressive angioleiomyoma is a benign but locally aggressive tumor, with a high recurrence rate, with spindle cells and myxoid stroma with prominent blood vessels and its immunohistochemistry reveals positivity for vimentin and, sometimes, for smooth muscle actin. Solitary fibrous tumor is a rare mesenchymal tumor, generally benign, but can be malignant. with

the proliferation of spindle cells and thick collagen; staghorn vessel pattern and immunohistochemistry positive for CD34 and STAT6, generally negative for S-100 and smooth muscle actin.<sup>9,10</sup>

Angioleiomyoma is a rare mesenchymal tumor, composed of a mixture of vascular and smooth muscle components, with histopathology showing small blood vessels and smooth muscle cells in the stroma and its immunohistochemistry being positive for smooth muscle actin and desmin, with some vessels expressing CD31. and CD34.<sup>10</sup> This is what was found by the pathological anatomy and cytopathology service.

The correct preoperative diagnosis of angioleiomyoma is challenging, mainly due to the absence of specific symptoms.<sup>1</sup> Local pain corresponds to the main finding, being present in up to 60% of cases,<sup>6</sup> as was shown by this patient. Thus, as it is an uncommon neoplasm when presented in the testicular region, few cases have been reported in the literature.

An article published by Elsayed, Afnan, Jaudah Al-Maghrabi, and Abdelrazak Meliti<sup>3</sup> in 2021 reported being the third case described in the English literature so far, making it the most recent case report found in the main databases of international medical literature.

As it is a rare tumor with unreliable imaging techniques to distinguish it from the main malignant testicular neoplasms, local resection was the chosen approach for the patient in question. This same approach was also described in other studies.<sup>3,7</sup> In addition, its nonspecific clinical presentation highlights the need for urologists to be aware of this condition, making this case report a direct contributor to increasing the visibility of this pathology.

## Responsabilidades Éticas

**Conflitos de Interesse:** Os autores declaram a inexistência de conflitos de interesse na realização do presente trabalho.

**Fontes de Financiamento:** Não existiram fontes externas de financiamento para a realização deste artigo.

**Confidencialidade dos Dados:** Os autores declaram ter seguido os protocolos da sua instituição acerca da publicação dos dados de doentes.



**Consentimento:** Consentimento do doente para publicação obtido.

**Proveniência e Revisão por Pares:** Não comissionado; revisão externa por pares.

#### *Ethical Disclosures*

**Conflicts of Interest:** *The authors have no conflicts of interest to declare.*

**Financing Support:** *This work has not received any contribution, grant or scholarship.*

**Confidentiality of Data:** *The authors declare that they have followed the protocols of their work center on the publication of data from patients.*

**Patient Consent:** *Consent for publication was obtained.*

**Provenance and Peer Review:** *Not commissioned; externally peer reviewed.*

#### **Declaração de Contribuição/Contributorship Statement:**

GCS – Idealização, coleta de dados, redação e revisão.

ACCT, LSSB, MVFD – Redação e revisão.

RGC – Revisão e orientação.

#### **Autor Correspondente/Corresponding Author:**

Gustavo Chaves de Souza.

Rua Professor Hélio Viana, 97, Itapoã, Belo Horizonte, Minas Gerais, Brasil. 31710330

E-mail: chvsgustavo@gmail.com

ORCID ID: 0000-0001-6341-2529

Recebido/Received: 2024-03-02

Aceite/Accepted: 2024-10-22

Publicado online/Published online: 2024-10-31

Publicado / Published:

© Author(s) (or their employer(s)) and Acta Urol Port 2024. Re-use permitted under CC BY-NC 4.0. No commercial re-use.

© Autor (es) (ou seu (s) empregador (es)) e Acta Urol Port 2024. Reutilização permitida de acordo com CC BY-NC 4.0. Nenhuma reutilização comercial.

#### **Referências**

1. Ramesh P, Annapureddy SR, Khan F, Sutaria PD. Angioleiomyoma: a clinical, pathological and radiological review. *Int J Clin Pract.* 2004; 58:587-91. doi: 10.1111/j.1368-5031.2004.00085.x.
2. Fletcher CD, Unni KK, Mertens F, editors. *Pathology and Genetics of Tumours of Soft Tissue and Bone.* Lyon; IARC Press; 2002.
3. Elsayed A, Al-Maghrabi J, Meliti A. Intra-testicular angioleiomyoma. A case report of a rare male urological entity. *Urol Case Rep.* 2021;40: 101913. doi: 10.1016/j.eucr.2021.101913.
4. Frias-Kletecka MC, MacLennan GT. Benign soft tissue tumors of the testis. *J Urol.* 2009;182:312-3. doi: 10.1016/j.juro.2009.04.020.
5. Nuciforo PG, Roncalli M. Pathologic quiz case: a scrotal sac mass incidentally discovered during autopsy. *Arch Pathol Lab Med.* 2003; 127:239-40. doi: 10.5858/2003-127-239-PQ.
6. Stimac G, Demirovic A, Kruslin B, Tomas D. Testicular angioleiomyoma presenting with haematospermia. *Asian J Androl.* 2013;15:573-4. doi: 10.1038/aja.2013.35.
7. Lavis R, Igbokwe U, Freeman S, Smith M. Intratesticular angioleiomyoma. *Arch Pathol Lab Med.* 2004;128:1165-6. doi: 10.5858/2004-128-1165-IA.
8. Weiss SW, Goldblum JR. *Enzinger and Weiss's Soft Tissue Tumors.* 6th ed. Amsterdam: Elsevier; 2014.
9. UStrakova-Peterikova A, Slisarenko M, Skopal J, Pivovarcikova K, Pitra T, Farcas M, et al. Familial syndromes associated with testicular and paratesticular neoplasms: a comprehensive review. *Virchows Arch.* 2024;484:723-31. doi: 10.1007/s00428-024-03803-x.
10. Fletcher CD, Bridge JA, Hogendoorn PC, Mertens F, editors. *WHO Classification of Tumours of Soft Tissue and Bone.* Lyon: IARC Press; 2013.