



Trexit: A “Clean” Withdrawal from Transrectal Prostate Biopsies – Prospective Results of In-office Freehand Transperineal Biopsies Under Local Anaesthesia

Trexit: Uma Saída “Limpa” das Biópsias Prostáticas Transretais – Resultados Prospetivos de Biópsias da Próstata “Mãos-Livres” no Consultório Sob Anestesia Local

Andreia Bilé Silva, Paulo Jorge Dinis, Frederico Portugal Gaspar, Rita Rodrigues Fonseca, José Carlos Santos

Abstract

Introduction: Prostate biopsy (PB) may be performed by either the transrectal (TR) or transperineal (TP) approach. Cancer detection rates seem to be comparable between the two approaches. However, evidence suggests a reduced infection risk and a higher detection of tumours localised in the anterior zone of the prostate with the TP route. TP-PB is currently recommended as a first-line procedure for the diagnosis of prostate cancer (PCa) whenever available.

We sought to report the initial results of in-office freehand TP-PB under local anaesthesia in the outpatient setting.

Methods: We conducted a prospective study with consecutive sampling with data from men submitted to TP-PB from Sep/2019 to Sep/2021, in a tertiary care centre. A questionnaire was carried out to appraise the pain related to the procedure on a pain numerical rating scale from 0 to 10.

Presenting PSA, biopsy result and characteristics and complications that motivated a visit to the emergency department–ED – until 1 month after the PB were analysed.

Antibiotic (AB) prophylaxis was not provided to any of the patients undergoing TP-PB.

TP-PB was performed under local anaesthesia by freehand method.

Results: A hundred and eight (108) patients underwent TP-PB. The mean age was 66 ± 9 years old.

The median presenting PSA was comparable in patients with positive and negative PB results (7.7 ng/mL, $p=0.11$).

Overall, 67/108 (62%) patients had PCa diagnosed. Clinically significant (cs) PCa (ISUP=2) was diagnosed in 42/67 (63%) patients.

The TP approach allowed the diagnosis of anterior zone PCa in 61% (41/67) of the patients (anterior zone csPCa in 63% of these), 7% (5/67) had exclusively anterior zone pathological findings.

Complications leading to an ED visit were recorded in only one patient.

Patients reported only mild levels of discomfort related to the anaesthesia infiltration (3 ± 3) and to the introduction of the US transducer (3 ± 3). Globally, the patients ascribed a pain of 3 ± 3 to the entire procedure.

Conclusion: Freehand TP-PB under local anaesthesia, without AB prophylaxis, is a well-tolerated and safe procedure, feasible as an outpatient procedure.

TP-PB provides an easy access to the anterior zone of the prostate allowing for the diagnosis of previously missed PCa.

Keywords: Image-Guided Biopsy; Prostate/pathology; Prostatic Neoplasms

Resumo

Introdução: A biópsia prostática (BxP) pode ser realizada por via transretal (TR) ou transperineal (TP). As taxas de deteção de neoplasia parecem comparáveis entre ambas as abordagens. Contudo, a evidência sugere um menor risco infeccioso e uma maior taxa de deteção de tumores localizados na porção anterior da próstata com a via TP. A BxP-TP é atualmente recomendada como procedimento de primeira linha no diagnóstico de cancro da próstata (CaP), sempre que disponível.

O trabalho tem como objetivo reportar os resultados iniciais de BxP-TP “mãos-livres” sob anestesia local, em regime de ambulatório.

Métodos: Realizou-se um estudo prospetivo com amostragem consecutiva e dados de homens submetidos a BxP-TP entre set/2019 e set/2021, num centro hospitalar terciário. Disponibilizou-se um questionário para avaliar a dor associada ao procedimento numa escala numérica de 0 a 10.

Hospital de Egas Moniz – Centro Hospitalar de Lisboa Ocidental E.P.E., Lisboa, Portugal

DOI: <https://doi.org/10.24915/aup.193>



Analisaram-se os PSA inicial, resultado e características da biópsia e complicações que motivaram uma ida ao Serviço de Urgência (SU) até um mês após a realização da BxP-TP.

Não se procedeu a administração de antibioterapia profilática em nenhum dos doentes submetidos a BxP-TP.

A BxP-TP foi efetuada sob anestesia local pelo método de “mãos-livres”.

Resultados: Um total de 108 doentes foram submetidos a BxP-TP. A idade média foi 66±9 anos.

O PSA inicial mediano foi comparável em doentes com BxP-TP com resultados positivo e negativo (7,7 ng/mL, $p=0,11$).

No total, 67/108 (62%) doentes foram diagnosticados com CaP, clinicamente significativo (CaPcs) (ISUP=2) em 42/67 (63%) destes.

A via TP permitiu diagnosticar CaP da zona anterior em 61% (41/67) dos doentes (CaPcs da zona anterior em 63% dos mesmos), 7% (5/67) tinham apenas positividade na zona anterior da próstata.

Apenas um doente teve complicações a condicionar necessidade de ida ao SU.

O procedimento causou apenas níveis ligeiros de desconforto associado à instilação de anestesia (3±3) e à introdução da sonda ecográfica (3±3). Globalmente, os doentes atribuíram uma dor de 3±3 ao procedimento na sua íntegra.

Conclusão: A BxP-TP “mãos-livres” sob anestesia local, sem antibioterapia profilática, é um procedimento bem tolerado, seguro, exequível em regime ambulatorial.

A via TP proporciona um acesso fácil à zona anterior da próstata, permitindo diagnosticar neoplasias cujo diagnóstico previamente se falhava.

Palavras-chave: Biópsia Guiada por Imagem; Neoplasia Prostática; Próstata/patologia

Introduction

According to GLOBOCAN, in 2020, prostate cancer was the fourth most common cancer worldwide, the second most common cancer in male (1 414 259 new cases) and the fifth leading cause of cancer-related death in men around the world.¹ In Portugal, 6759 new cases of prostate cancer were diagnosed with 1917 deaths from the disease, it being the third most frequent cancer nationwide and the most prevalent in male.¹ Thus, it is vital to improve early detection of PCa techniques.

More than 2 million prostate biopsies (PB) are estimated to be carried out annually in the United States and Europe, being the most commonly performed diagnostic procedure in urology.^{2,3}

In 1922, the first PB was performed using the transperineal (TP) route. The transrectal (TR) method followed, 15 years later. By then, prostate biopsies were performed without any kind of image guidance. In 1989 Hodge *et al* began using transrectal ultra-

sound-guided (TRUS) PB^{4,5} and Stamey and colleagues suggested the systematic sextant PB template.⁶ The technique has been refined since then. Nevertheless, by the late 1990's, some of the TRUS-PB shortcomings became evident, namely its missing up to 30% of prostate tumours and being unable to sample the entire prostate.^{5,6}

Ultrasound-guided PB is currently the standard of care either performed by the transrectal or transperineal approach.² The main differences consist in the puncture site: whereas TP--PB relies on puncturing the perineum in order to obtain prostatic access, TR--PB is performed through puncture of the anterior rectal wall.⁴

However, the increasing number of infectious complications secondary to TR-PB occurring in up to 7% of patients (with 3% of patients undergoing TR-PB requiring hospitalization) as well as the growing resistance to antimicrobials urged the search for alternatives to TR-PB. The reduction of the infectious risk may be prompted by administration of antimicrobials and/or technical modifications to the PB. TP-PB seems to be an option since its infectious complications are extremely rare due to avoiding the rectal flora.^{3,5-10}

Nonetheless, the oncological outcomes, namely cancer detection rates, seem to be comparable between both approaches.⁴ Hence, the 2021 European Association of Urology (EAU) guidelines recommend TP-PB as a first-line procedure for the diagnosis of prostate cancer (PCa) whenever available.¹¹ Even so, most clinicians remain reluctant to perform a TP-PB allegedly due to logistical challenges. Most of them feel the approach to be counterintuitive due to unfamiliarity, regard the technique as expensive and time-consuming and mention the need for general anaesthesia as well as the absence of a standardised template as some of the drawbacks of the procedure.^{6,7,9} Furthermore, freehand TP-PB allows for the diagnosis of PCa in areas that were not properly sampled when using the TR route, namely the apical and anterior zones.^{5-7,10}

Currently, there is a growing interest in implementing TP-PB as a routine practice.

In the current study, we sought to report the initial results of in-office freehand TP-PB under local anaesthesia in an outpatient setting concerning the feasibility, safety and reproducibility of the procedure, its cancer detection and complication rates. For that, a prospective study was conducted.

Material and Methods

We conducted a prospective single-institution study with consecutive sampling. Data from men submitted to TP-PB with US guidance from September 2019 to September 2021, in a tertiary care centre, was collected.

Patients' demographics and comorbidities (Charlson Comorbidity Index – CCI) were assessed.



Patients underwent PB due to suspicious digital rectal examination findings, elevated PSA, suspicious findings on multiparametric magnetic resonance imaging (mpMRI) or a combination of those. Additionally, patients included in an active surveillance protocol for previously diagnosed low-risk PCa were submitted to PB. Most of the patients had mpMRI prior to the PB (58%).

A questionnaire was carried out to appraise the pain related to the procedure on a pain numerical rating scale from 0 to 10. Patients pointed out their pain during ultrasound probe insertion, anaesthesia infiltration and the procedure, globally.

Presenting PSA, pathological result, and biopsy characteristics (PCa detection and complications that motivated a visit to the emergency department –ED– until 1 month after the PB) were analysed. We considered clinically significant PCa (csPCa) as ISUP=2.

Antibiotic (AB) prophylaxis was not provided to any of the patients undergoing TP-PB.

All participants provided written informed consent with guarantees of confidentiality.

Patient Positioning

Dorsal lithotomy position was used. Scrotal elevation from the perineum was obtained with tape. The perineum was cleaned with povidone-iodine.

Transrectal ultrasound was performed with a 14-4MHz endocavitary transducer (BK medical), which is a triplanar ultrasound

probe BK® 3000. Whenever previously unknown, prostate volume was estimated using the traditional measurements (height, width and length).

An anal cellulose-based lubricant with local anaesthetic (lidocaine 2%) and disinfecting properties (Instillagel®) was used.

Perineal Puncture Location and Local Anaesthetic Block

TP-PB was performed under local anaesthesia (1% lidocaine hydrochloride). The access point was estimated taking into account the estimated prostatic volume, considering the median raphe and the far lateral edge of the prostate on each side. The puncture is usually placed 2-2.5 cm above the anterior anal margin and 1-1.5 cm lateral to the perineal median raphe.

A bilateral perineal subcutaneous block (2.5 mL of 1% lidocaine), followed by a bilateral pelvic floor muscles block (5 mL of 1% lidocaine) and a periprostatic block (5 mL of 1% lidocaine) were combined. Approximately 25 mL of 1% lidocaine hydrochloride were infiltrated to accomplish the block. Afterwards, two 14-gauge Abbocath® catheters were inserted in the pre-anaesthetised area in order to provide access to both left and right prostatic lobes percutaneously.

Prostate Biopsy Technique

Fig. 1 illustrates the table for the biopsy technique.

The transperineal prostate biopsy comprised a minimum of 14 cores (14-core template – including sampling of the anterior zone

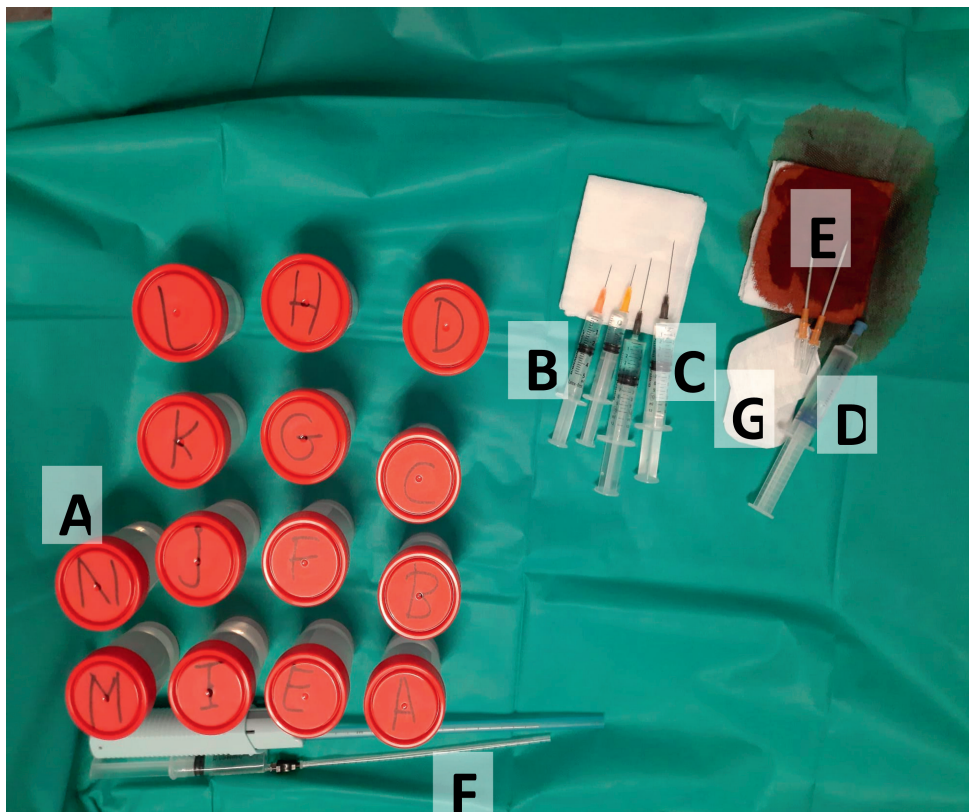


Figure 1 – Table displaying the necessary material to perform a transperineal prostate biopsy

A – 14 tubes containing 4% formalin to save the cores; B – subcutaneous anaesthesia (2.5 cm³ of 1% lidocaine in two syringes); C – intramuscular anaesthesia (5 cm³ of 1% lidocaine in two syringes); D – cellulose-based lubricant with local anaesthetic (lidocaine 2%) and disinfecting properties (Instillagel®); E – two 14-gauge Abbocath® catheters; F – long needle to perform periprostatic block (10 cm³ of 1% lidocaine to divide for the two lobes of the prostate); G – two plasters to cover the perineal puncture sites following the procedure



of the prostate) and additional cores targeting suspicious lesions found on the mpMRI of the prostate (cognitively). The systematic collection of 14 cores was performed bilaterally as follows (Fig. 2): anterior apical, posterior apical, median posterior mid-third, lateral posterior mid-third, median anterior mid-third, lateral anterior mid-third, base. Each biopsy specimen was placed individually in tubes containing 4% formalin, except for those targeting suspicious lesions, which were all placed in the same tube (3 cores per suspicious lesion).

All biopsies were performed with the Magnum™ 18Gx20cm needle, (Bard Biopsy Systems®, Tempe, AZ) by freehand method.

Statistical Analysis

A descriptive analysis is presented. Categorical variables were presented as frequencies or percentages. Continuous variables were reported as mean ± standard deviation.

To determine whether the data had a Gaussian distribution, Gaussian curve and Kolmogorov-Smirnov test were used.

The statistical analyses were conducted using SPSS version 25 (IBM corporation, New York, USA). Statistically significant results were considered as *p* inferior to 0.05.

Results

A total of hundred and eight (108) patients underwent TP-PB in our centre over the 2-year period. The mean age of the cohort was 66±9 years old. Twenty-six out of the 108 (24.1%) had undergone a previous TR-PB and were included in the study.

The mean prostate volume was 55±33 cm³.

Charlson Comorbidity Index had a mean value of 4±2.

The main reasons motivating TP-PB were elevated PSA (26.9%) and elevated PSA combined with suspicious findings on multiparametric MRI (25.9%) (Table 1).

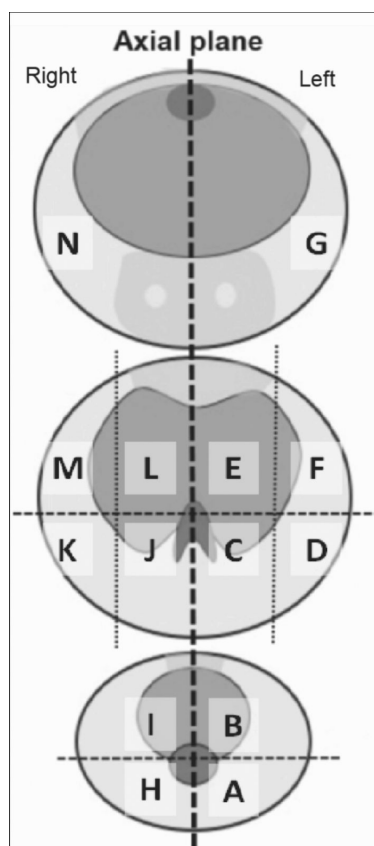


Figure 2 – 14-core template used to perform the transperineal prostate biopsy

Left side:

A – posterior apical; B – anterior apical; C – median posterior mid-third; D – lateral posterior mid-third; E – median anterior mid-third; F – lateral anterior mid-third; G – base

Right side:

H – posterior apical; I – anterior apical; J – median posterior mid-third; K – lateral posterior mid-third; L – median anterior mid-third; M – lateral anterior mid-third; N – base

Most of the patients (63, 58%) underwent mpMRI prior to the PB. A total of 33 patients with a positive TP-PB result had suspicious lesions in a previous mpMRI (33/63, 52%). From those, 19 (58%) were found to have positive PB cores in locations matching the ones stated in the imaging.

Overall, 67/108 (62%) patients had PCa diagnosed. The mean percentage of positive cores was 35% (95% CI 28-41%) and the

Table 1 – Indications for transperineal prostate biopsy

Indications	Patients submitted to TP-PB (n=108)
Suspicious DRE (percentage)	5 (4.6)
Elevated PSA (percentage)	29 (26.9)
Patients in active surveillance protocol (percentage)	9 (8.3)
Suspicious DRE and elevated PSA (percentage)	24 (22.2)
Elevated PSA and suspicious findings on mpMRI (percentage)	28 (25.9)
Suspicious findings on mpMRI (percentage)	4 (3.7)
Suspicious DRE, elevated PSA and suspicious findings on mpMRI (percentage)	9 (8.3)

DRE – digital rectal examination; mpMRI – multiparametric magnetic imaging resonance; TP-PB – transperineal prostate biopsy



median percentage of maximum positive core length of 60% (95% CI 49-65%). Clinically significant (cs) PCa (ISUP=2) was diagnosed in 63% (42/67) of the diagnosed patients. From those with a positive TP-PB, most had non-clinically significant PCa (ncsPCa) – ISUP 1 in 37.3%, as showed in Table 2. ISUP 2, 3, 4 and 5 were found in 20.9%, 19.4%, 13.4% and 7.5% of patients, respectively.

The TP approach allowed the diagnosis of anterior zone PCa in 61% (41/67) of the patients (anterior zone csPCa in 63% of these), 7% (5/67) had exclusively anterior zone pathological findings (Table 2).

Complications leading to an Emergency Department (ED) visit were recorded in only one patient: an event of febrile urinary tract infection, which led to acute urinary retention. In the remaining 107 patients, no complications were reported.

Patients tolerated the transperineal approach reasonably well and reported only mild levels of discomfort related to the anaesthesia infiltration (3±3, interquartile range: 4) and to the introduction of the US transducer (3±3, interquartile range: 5). Globally, the patients ascribed a pain of 3±3 to the entire procedure (interquartile range: 4). Patients reported feeling no pain at all (0/10) during the three steps of the procedure in 18, 26 and 20 cases, respectively.

Discussion

Transrectal prostate biopsy remained as the gold-standard for the diagnosis of prostate cancer for several years.^{12,13} Nevertheless,

this technique involves a significant infectious complication rate and does not allow for proper sampling of the anterior and apical regions of the prostate.¹³

Transperineal prostate biopsy was regarded as an alternative for the diagnosis of PCa. Nonetheless, it being performed under general anaesthesia thus requiring an operating room and a larger team to accomplish the procedure, were deemed as drawbacks of this approach.^{12,14} Our results show that it is not only feasible in the outpatient setting but also safe and oncologically reasonable.

The transrectal route implies the passage of a needle through the rectum. The transperineal approach allows the biopsy gun punctures to be performed through disinfected perineal skin, instead. The increasing number of multi-resistant bacteria is leading to an increase in the infectious complication rate when TR-PB are performed with a reported incidence of 0.1%-7% and hospital admissions reaching 4.1%. Concerning bacteraemia, it occurs in up to 3%-6.9% of patient undergoing TR-PB and in up to one-quarter of those requiring Intensive Care Unit monitoring and treatment.^{12,15}

Several measures, antibiotic and nonantibiotic ones, have been advocated towards diminishing infectious complications. A review on strategies to reduce infectious complications after prostate biopsy conducted by Pilatz *et al* revealed that rectal preparation with povidone-iodine and antibiotic prophylaxis were of significant value to reduce infectious complications. Augmented and targeted antibiotic prophylaxis showed some potential

TABLE 2 – Biopsy results and pathologic characteristics and specific findings concerning anterior zone prostate cancer

	Patients with positive TP-PB (n=67)
ISUP grade	
- ISUP 1 (percentage)	26 (38.8)
- ISUP 2 (percentage)	14 (20.9)
- ISUP 3 (percentage)	13 (19.4)
- ISUP 4 (percentage)	9 (13.4)
- ISUP 5 (percentage)	5 (7.5)
Perineural invasion (percentage)	18 (26.9)
Lymphovascular invasion (percentage)	1 (1.5)
Extraprostatic extension (percentage)	1 (1.5)
Cribiform pattern (percentage)	2 (3)
Anterior zone PCa (percentage)	41 (61.2)
exclusively anterior zone PCa (percentage)	5 (7.5)

ISUP – International Society of Urological Pathology; PCa – prostate cancer; TP-PB – transperineal prostate biopsy



but require further validation prior to their recommendation.¹⁶ In an editorial from the same author on the prevention of infectious complications following prostate biopsy, transperineal prostate biopsy is defended towards reaching a lower sepsis rate (0.1%) compared to the one obtained through the rectal route (0.9%).¹⁷ Finally, in another more recent review, Pradere *et al* acknowledge the significance of TP-PB suggesting it as the preferred approach to diagnose PCa.¹⁸ A meta-analysis including seven randomised-controlled trials demonstrated TP-PB to be associated with significantly fewer infectious complications when compared to TR-PBs and a systematic review which included 165 studies concluded that sepsis rates of 0.1% and 0.9% are found when performing TP-PB and TR-PB, respectively.⁸ Literature comparing other complications following TP-PB and TR-PB reported similar outcomes through both approaches.⁵

Even so, when performing TP-PB, complications other than the infectious ones should be taken into account. A recent meta-analysis comparing the transperineal and the transrectal techniques has showed comparable non-infectious complications with both techniques, with a trend towards a higher acute urinary retention rate in the TP-PB cohort.¹⁹ One of the most common complications with TP-PB is haematuria (2%-84%). Haematospermia and perineal haematoma have also been described.^{9,12,13,15,19} In our study, only one patient out of the 108 included had complications following TP-PB, a febrile urinary infection leading to acute urinary retention, highlighting the residual percentage of infectious complications through this approach.

Different antibiotic prophylaxis protocols may be found in the literature. While some authors recommend oral fluoroquinolones (started the day before the procedure and continued for a total of 3 days),²⁰ others recommend a single dose of oral cephalexin or cefuroxime (2 hours prior to the procedure) and adequate intravenous agents in patients with replaced cardiac valves.^{9,13} As in our study, some authors support the omission of antibiotic prophylaxis^{13,21,22} or only give it to patients with previous infections after transrectal biopsy providing appropriate endocarditis prophylaxis to patients with mechanical heart valves or other risk factors.²²

Previous studies had established a similar PCa detection rate between the two biopsy techniques, supporting TP-PB as a diagnostic technique comparable to TR-PB.^{5,6,9,13} In our study, PCa was detected in 62% (67/108) of the patients submitted to TP-PB, which compares favourably with historical 10-12-core TR-PB cohorts with an overall PCa detection rates ranging from 20.3% to 44.4%.¹³ Anterior zone PCa was identified in 41 patients. Although most studies point towards 20%-30% of anterior zone PCa, we obtained a higher proportion (61.2%, 41/67). In accordance with a study from Stefanova *et al*, this finding underscores the previously underestimated representation of PCa in this location.⁹

In the current study, patients reported only a slight pain during anaesthesia infiltration, introduction of the transducer and the entire procedure, underlining its feasibility in the outpatient setting, under local anaesthesia, already vastly documented in the literature.^{9,12,14,23} This finding, combined with the satisfactory PCa detection rates and low complication rates, places TP-PB as a reliable option to the previously worldwide performed TR-PB, greatly impacting on healthcare systems since it will decrease inpatient costs allowing for a more sustainable management of available resources. Local anaesthesia is not only safe but also efficient.¹⁴ Furthermore, switching to the transperineal approach does not increase material costs since biopsies are performed with the available technology.

Limitations of this study include lack of randomization in a relatively small study population of 108 patient cases collected in a single institution and the lack of a control group. Larger sample size and randomized controlled trials should be considered for validation of our findings.

Conclusion

In the present study, we provide meaningful evidence that in-office freehand TP-PB under local anaesthesia, without AB prophylaxis, is a well-tolerated and safe procedure, feasible as an outpatient procedure.

TP-PB provides an easy access to the anterior zone of the prostate allowing for the diagnosis of previously missed PCa.

Furthermore, the results highlight the accuracy of the TP approach targeting suspicious lesions found on mpMRI.

Responsabilidades Éticas

Conflitos de Interesse: Os autores declaram a inexistência de conflitos de interesse na realização do presente trabalho.

Fontes de Financiamento: Não existiram fontes externas de financiamento para a realização deste artigo.

Confidencialidade dos Dados: Os autores declaram ter seguido os protocolos da sua instituição acerca da publicação dos dados de doentes.

Proteção de Pessoas e Animais: Os autores declaram que os procedimentos seguidos estavam de acordo com os regulamentos estabelecidos pela Comissão de Ética responsável e de acordo com a Declaração de Helsínquia revista em 2013 e da Associação Médica Mundial.

Proveniência e Revisão por Pares: Não comissionado; revisão externa por pares.

Ethical Disclosures

Conflicts of Interest: *The authors have no conflicts of interest to declare.*

Financing Support: *This work has not received any contribution, grant or scholarship*



Confidentiality of Data: *The authors declare that they have followed the protocols of their work center on the publication of data from patients.*

Protection of Human and Animal Subjects: *The authors declare that the procedures followed were in accordance with the regulations of the relevant clinical research ethics committee and with those of the Code of Ethics of the World Medical Association (Declaration of Helsinki as revised in 2013).*

Provenance and Peer Review: *Not commissioned; externally peer reviewed.*

Declaração de Contribuição/Contributorship Statement:

ABS e PJD: Conception, interpretation of data for the work; drafting the work, revision and final approval of the version to be published

FPG, RRF, JCS and LAM: Revision and final approval of the version to be published

Autor Correspondente/Corresponding Author:

Bilé Silva, A.

Hospital de Egas Moniz, Rua da Junqueira, 126 1349-019 LISBOA

Email: andreiabile@campus.ul.pt

ORCID:0000-0003-2429-2688

Recebido/Received:

Aceite/Accepted: 2022-10-24

Publicado online/Published online: 2024-1-10

Publicado/Published: 2024-03-1

© Author(s) (or their employer(s)) and Acta Urol Port 2023. Re-use permitted under CC BY. No commercial re-use.

© Autor (es) (ou seu (s) empregador (es)) e Acta Urol Port 2023. Reutilização permitida de acordo com CC BY. Nenhuma reutilização comercial.

References

1. World Health Organization. Portugal - Global Cancer Observatory. Globocan. 2020. 2020;501:1-2. [accessed Oct 2022] Available at: <https://gco.iarc.fr/today/data/factsheets/populations/620-portugal-fact-sheets.pdf>
2. Borghesi M, Ahmed H, Nam R, Schaeffer E, Schiavina R, Taneja S, et al. Complications After Systematic, Random, and Image-guided Prostate Biopsy. *Eur Urol.* 2017;71:353-65. doi: 10.1016/j.eururo.2016.08.004.
3. Pradere B, Veeratterapillay R, Dimitropoulos K, Yuan Y, Omar MI, MacLennan S, et al. Nonantibiotic strategies for the prevention of infectious complications following prostate biopsy: a systematic review and meta-analysis. *J Urol.* 2021;205:653-63. doi:10.1097/JU.0000000000001399
4. Guo LH, Wu R, Xu HX, Xu JM, Wu J, Wang S, et al. Comparison between ultrasound guided transperineal and transrectal prostate biopsy: a prospective, randomized, and controlled trial. *Sci Rep.* 2015;5:1-10. doi:10.1038/srep16089
5. Bhatt NR, Breen K, Haroon UM, Akram M, Flood HD, Giri SK. Patient experience after transperineal template prostate biopsy compared to prior transrectal ultrasound guided prostate biopsy. *Centr Eur J Urol.* 2018;71:43-7. doi:10.5173/cej.2017.1536
6. Ristau BT, Allaway M, Cendo D, Hart J, Riley J, Parousis V, et al. Free-hand transperineal prostate biopsy provides acceptable cancer detection and minimizes risk of infection: evolving experience with a 10-sector template. *Urol Oncol.* 2018;36:528.e15-528.e20. doi:10.1016/j.urolonc.2018.09.013
7. Lv Z, Jiang H, Hu X, Yang C, Chand H, Tang C, et al. Efficacy and safety of periprostatic nerve block combined with perineal subcutaneous anaesthesia and intrarectal lidocaine gel in transrectal ultrasound guided transperineal prostate biopsy: A Prospective Randomised Controlled Trial. *Prostate Cancer Prostatic Dis.* 2020;23:74-80. doi: 10.1038/s41391-019-0155-0.
8. Pilatz A, Veeratterapillay R, Dimitropoulos K, Omar MI, Pradere B, Yuan Y, et al. European Association of Urology Position Paper on the Prevention of Infectious Complications Following Prostate Biopsy. *Eur Urol.* 2021;79:11-5. doi: 10.1016/j.eururo.2020.10.019.
9. Stefanova V, Buckley R, Flax S, Spevack L, Hajek D, Tunis A, et al. Transperineal Prostate Biopsies Using Local Anesthesia: Experience with 1,287 Patients. Prostate Cancer Detection Rate, Complications and Patient Tolerability. *J Urol.* 2019;201:1121-6. doi: 10.1097/JU.000000000000156.
10. McGrath S, Christidis D, Clarebrough E, Ingle R, Perera M, Bolton D, et al. Transperineal prostate biopsy - tips for analgesia. *BJU Int.* 2017;120:164-7. doi: 10.1111/bju.13859.
11. Mottet N, Bellmunt J, Bolla M, Briers E, Cumberbatch MG, De Santis M, et al. EAU-ESTRO-SIOG Guidelines on Prostate Cancer. Part 1: Screening, Diagnosis, and Local Treatment with Curative Intent. *Eur Urol.* 2017;71:618-29. doi: 10.1016/j.eururo.2016.08.003.
12. Huang GL, Kang CH, Lee WC, Chiang PH. Comparisons of cancer detection rate and complications between transrectal and transperineal prostate biopsy approaches - A single center preliminary study. *BMC Urol.* 2019;19:1-8. doi:10.1186/s12894-019-0539-4
13. Ristau BT, Allaway M, Cendo D, Hart J, Riley J, Parousis V, et al. Free-hand transperineal prostate biopsy provides acceptable cancer detection and minimizes risk of infection: evolving experience with a 10-sector template. *Urol Oncol.* 2018;36:528.e15-528.e20. doi: 10.1016/j.urolonc.2018.09.013.
14. Lv Z, Jiang H, Hu X, Yang C, Chand H, Tang C, et al. Efficacy and safety of periprostatic nerve block combined with perineal subcutaneous anaesthesia and intrarectal lidocaine gel in transrectal ultrasound guided transperineal prostate biopsy: A Prospective Randomised Controlled Trial. *Prostate Cancer Prostatic Dis.* 2020;23:74-80. doi: 10.1038/s41391-019-0155-0.
15. Bhatt NR, Breen K, Haroon UM, Akram M, Flood HD, Giri SK. Patient experience after transperineal template prostate biopsy compared to prior transrectal ultrasound guided prostate biopsy. *Cent European J Urol.* 2018;71:43-7. doi:10.5173/cej.2017.1536
16. Pilatz A, Veeratterapillay R, Köves B, Cai T, Bartoletti R, Wagenlehner F, et al. Update on Strategies to Reduce Infectious Complications



- After Prostate Biopsy. *Eur Urol Focus*. 2019;5:20-8. doi: 10.1016/j.euf.2018.11.009.
17. Pilatz A, Veeratterapillay R, Dimitropoulos K, Omar MI, Pradere B, Yuan Y, et al. European Association of Urology Position Paper on the Prevention of Infectious Complications Following Prostate Biopsy. *Eur Urol*. 2021;79:11-5. doi: 10.1016/j.eururo.2020.10.019.
18. Pradere B, Veeratterapillay R, Dimitropoulos K, Yuan Y, Omar MI, MacLennan S, et al. Nonantibiotic Strategies for the Prevention of Infectious Complications following Prostate Biopsy: A Systematic Review and Meta-Analysis. *J Urol*. 2021;205:653-63. doi: 10.1097/JU.0000000000001399.
19. Xue J, Qin Z, Cai H, Zhang C, Li X, Xu W, et al. Comparison between transrectal and transperineal prostate biopsy for detection of prostate cancer: a meta-analysis and trial sequential analysis. *Oncotarget*. 2017;8:23322-36. doi:10.18632/ONCOTARGET.15056
20. Mantica G, Pacchetti A, Aimar R, Cerasuolo M, Dotta F, Olivero A, et al. Developing a five-step training model for transperineal prostate biopsies in a naïve residents' group: a prospective observational randomised study of two different techniques. *World J Urol*. 2019;37:1845-50. doi: 10.1007/s00345-018-2599-6.
21. Meyer AR, Joice GA, Schwen ZR, Partin AW, Allaf ME, Gorin MA. Initial Experience Performing In-office Ultrasound-guided Transperineal Prostate Biopsy Under Local Anesthesia Using the PrecisionPoint Transperineal Access System. *Urology*. 2018;115:8-13. doi: 10.1016/j.urology.2018.01.021.